

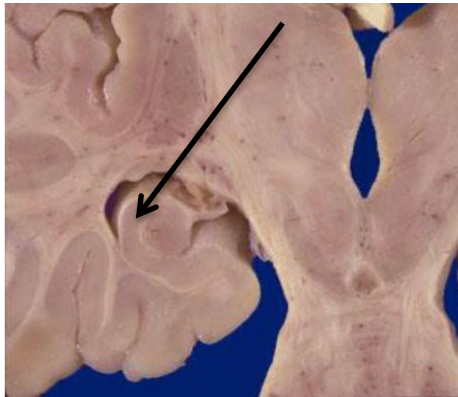
# NS Lab



subject	
anatomy	Dr. Ezidin & Dr. Abdulameer
physio	Dr. Reyad
patho	Dr. Shifaa
Micro	Dr. Hala

## Anatomy lab:

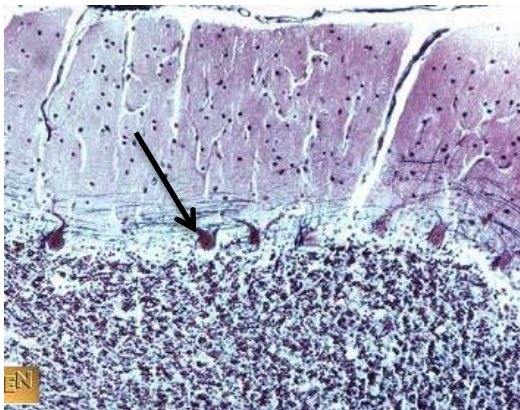
1) Identify the structure :



BAU#1

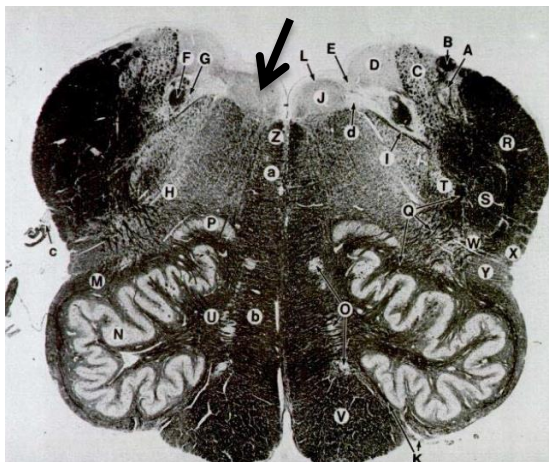
- Hippocampus

2) What is type of the cell?



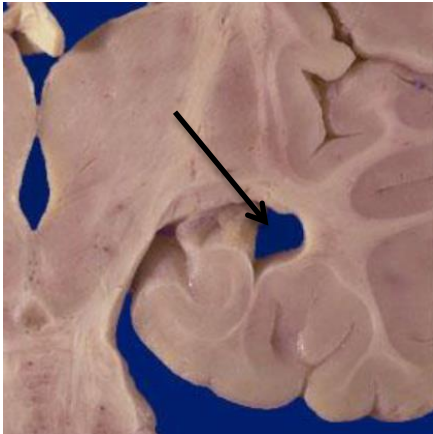
- Purkenji cells

3) Name the structure :



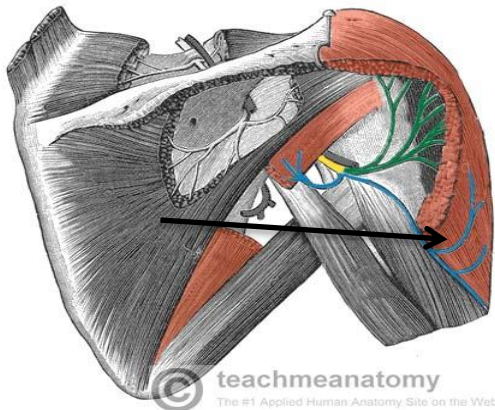
- Hypoglossal nucleus

4) Name the structure (be specific):



- Inferior horn of lateral ventricle

5) Name the structure:

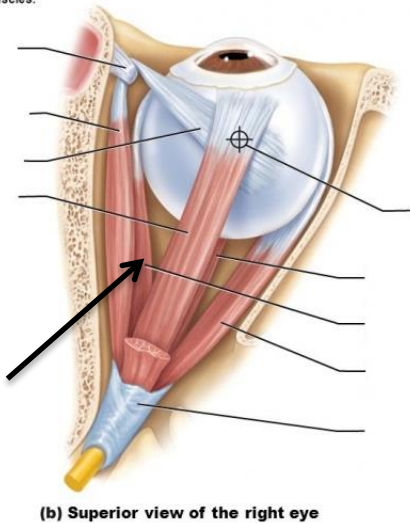


(note: I couldn't find the original pic as the one in the exam but it was clear one, on plastinated upper limb with deltoid muscle only)

- Axillary nerve

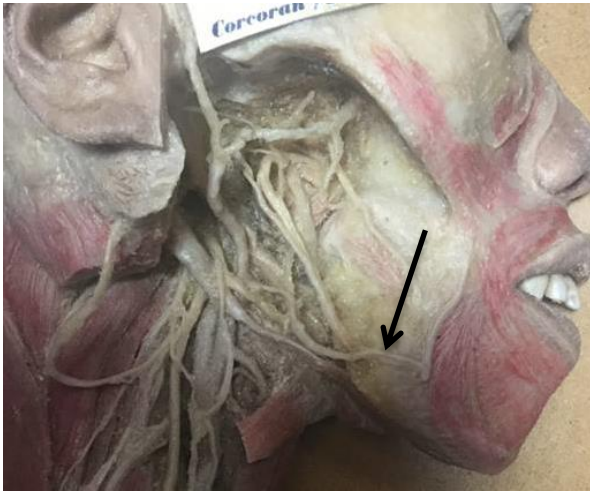6) The following structure is innervated by:

Figure 15.3b Extrinsic eye muscles.



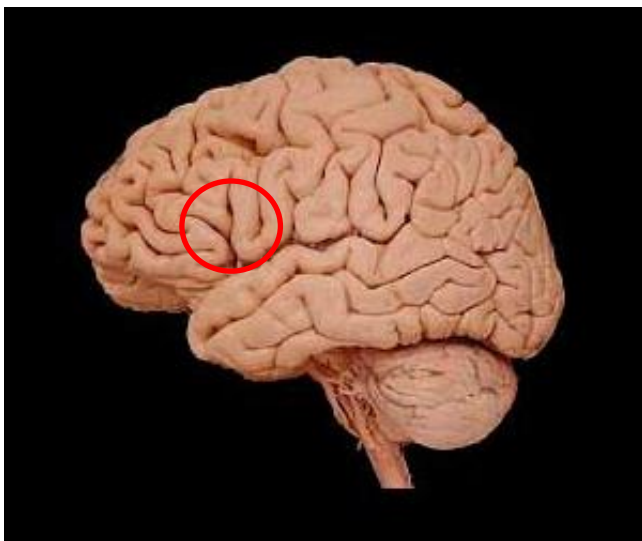
- Oculomotor nerve

7) Identify the structure:



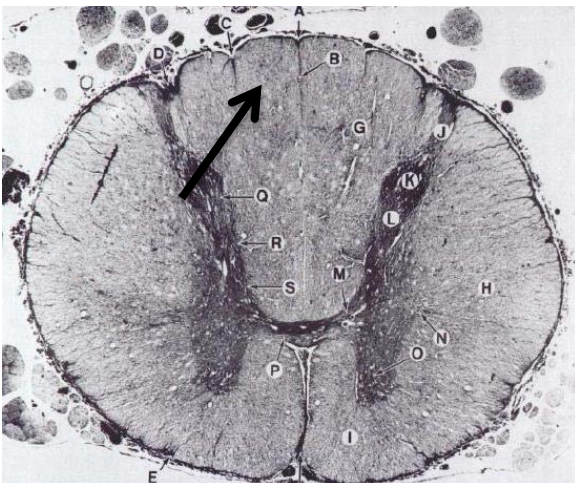
- Facial artery

8) Identify the circled structure



- Broca's area

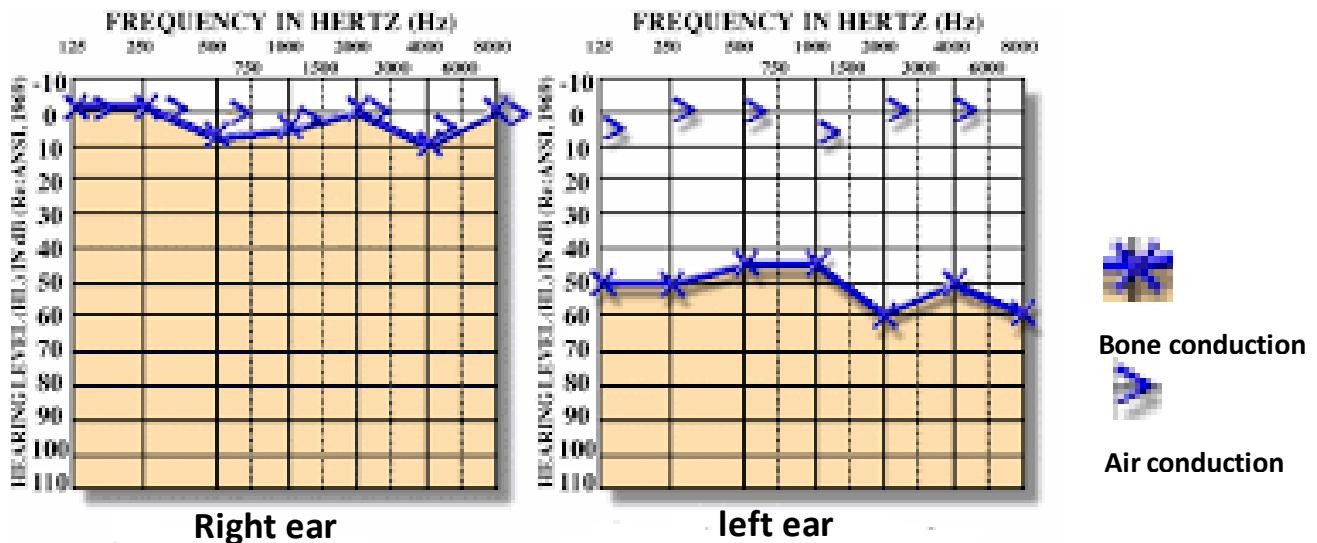
9) Name the structure



- Gracile fasciculus

## Physio lab:

10) From the following Audiogram which of the following is correct:



- normal right, conductive left

11) Jendrassik maneuver used in examination of:

- knee jerk

12) If you are looking to something that is 6m away from you. Which of the following is correct :

- Low curvature lens ----- mydriasis ----- receiving parallel light rays

## Micro lab:

13) Some long long case indicates bacterial meningitis. On Gram smears of CSF demonstrate Gram-negative diplococci. What is the causative agent?

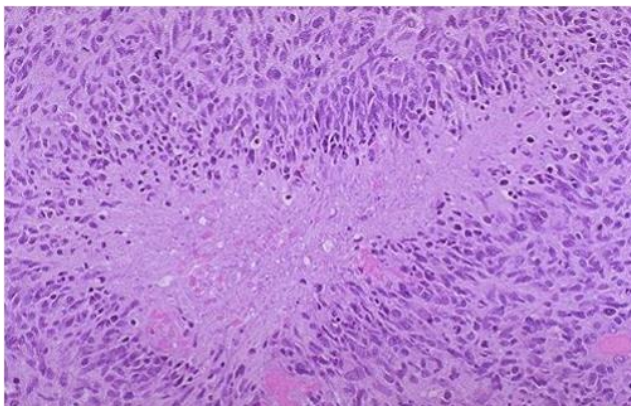
- n.meningitidis

14) Regarding LP which of the following statement is true:

- third tube is used for hematology test

## Patho lab:

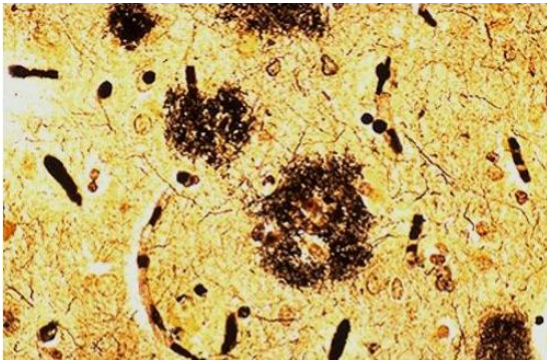
15) The following pic is for brain biopsy from a living pt. what is median survival in this case?



- 15 months

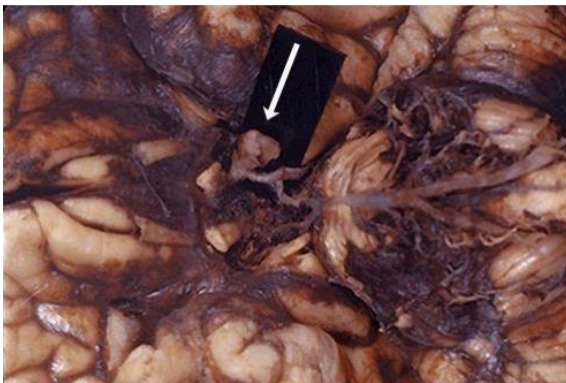


16) The following deposition is made of:



- beta amyloid (Alzheimer)

17) If the following structure ruptured what type of hemorrhage could occur:



- Subarachnoid hemorrhage

### Cases:

18) Which of the following occur in case of lateral lesion in medulla but not in lateral lesion in pons:

- Hoarseness of the voice (cuz its related to nucleus ambiguous)

19) Grand Mal is also known as

- tonic-clonic

20) What type of seizures that seen in children or infants, caused by cerebral pathology, often with mental retardation:

- myoclonic

\*\*that was the whole lab exam.. Wish you a good luck

*"Start where you are..*

*Use what you have ..*

*Do what you can"*

Collected by: Ahmad Al-Masri

Good Luck